

See discussions, stats, and author profiles for this publication at: <https://www.researchgate.net/publication/311970378>

78 EFFECT OF HONEY BEE POLLEN AQUEOUS SUSPENSION ON SPERMATOGENIC ACTIVITY OF MALE RABBITS

Article in *Basrah Journal of Veterinary Research* · January 2015

CITATIONS

0

READS

92

3 authors, including:



[Alaa Abdulkhalek Sawad](#)

University of Basrah

44 PUBLICATIONS 62 CITATIONS

SEE PROFILE

Some of the authors of this publication are also working on these related projects:



Study the effect of Coenzyme Q10 (Co Q10) and Dehydroepiandrosterone (DHEA) and their combination on reproductive and biochemical parameters on carbon tetrachloride (CCL4) induced adult albino male rats [View project](#)

EFFECT OF HONEY BEE POLLEN AQUEOUS SUSPENSION ON SPERMATOGENIC ACTIVITY OF MALE RABBITS

Ihsan A. Habbib , Alaa A. Sawad, Zainab Bakir

College of Veterinary Medicine, University of Basrah,Basrah, Iraq.

(Received 13May 2015 ,Accepted 26May 2015)

Key words: Rabbits, Seminiferous tubules, Spermatozoa

ABSTRACT

The study was conducted to evaluate the histological effect of bee pollen grains at the testis in rabbits. Twenty male rabbits were divided into two equal groups, the first administrated with normal saline orally, the second group treated by bee pollen aqueous suspension, Histological observation showed an increase in the number and size of seminiferous tubules containing spermatozoa with the invasion of blood vessels in comparison with the control group

INTRODUCTION

Bee pollen considers as one of the natural feed supplements which largely used in animal and human The bee pollen from an important food rich in protein, carbohydrates and fats and a large number of minerals and vitamins, which considers very useful for animals and humans (1)

Pollen was a fine powder collected by bees from flowering plants and considered as the male gametophytes and an important source of bee foods (2).

The animals that treated with bee pollen shows a significant increase of body weights and blood parameters, that's led to consider the bee pollen as a good feed additives (3)

The bee pollen was very useful to increase the blood hemoglobin, and regulated the level of cholesterol of blood also noticed (4). The histological changes of fish testis treated with bee pollen and Propolis showed an increased at the spermatogonia at the lumen of the somniferous tubules, while the walls of the tubules appeared thinner that of untreated *Oreochromis niloticus*. (5)

MATERIALS AND METHODS

Animals;

Twenty healthy male rabbits, 1800gm average weight were housed at room temperature under natural photoperiod and maintained on a standard pellet diet and tap water (6).

Pollen Samples:

The bee pollen obtained from Basrah market, dried at 37 C° and then ground into powder. The animals were divided into two groups, first group selected as control and administrated orally with normal saline daily by gavage needle, While the treated group orally assigned bee pollen powder suspension (5gm) daily for eight weeks(5).

Experimental Design:

At eight weeks of the experiment, the animals of all groups were anesthetized with ketamine (35 mg/kg) and xylazine (5 mg/kg) intramuscularly, and scarified via heart puncture, the testis were removed, and fixed in Bouin's solution, dehydrated in a graded series of ethanol, cleared in xylene, embedded in paraffin, and finally sectioning and stained sections were mounted with DPX and examined using light microscope (7).

RESULTS

The histological features of the testis include the seminiferous tubules which lined with a stratified epithelial cells and Sertoli (Fig.1). That lies in the basement membrane of the tubules with different stages of spermatogenic cells, the primary and secondary spermatocytes, the spermatids aggregates in a cluster at the lumen of the tubules (Fig.2).

Sertoli cells are fewer in number and considered as a supporting cells, they are tall cell and extended from the basement membrane into the lumen and have a triangular nucleus

The testis shows the a thin tunica with a number of seminiferous tubules which includes A large numbers of spermatogenic stages in comparisons with control group(Fig.3).in addition to the invation of congested blood vessels (Fig. 4)

Different spermatogenic stages; spermatogonia, spermatocytes, spermatids and sperms; in addition to the interstitial connective tissue that surrounded the seminiferous tubules

In the treated group with bee pollen powder, the testis seminiferous tubules lumen is small with a large number of sperm producing cells in comparison with control group.

On the other hand, there is an increased at the size of interstitial cells, and an aggregation of the sperms at the lumen of the seminiferous tubules.(Fig.5).

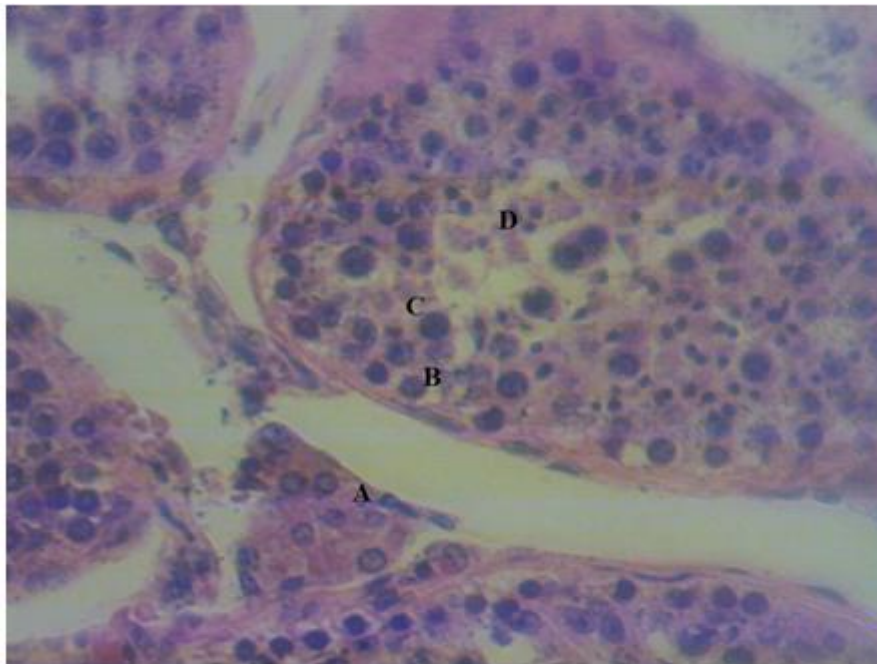


Fig 1:Control group, A-Ledig cell, B-primary spermatocyte, C-Secondary spermatocyte, D-Spermatid.

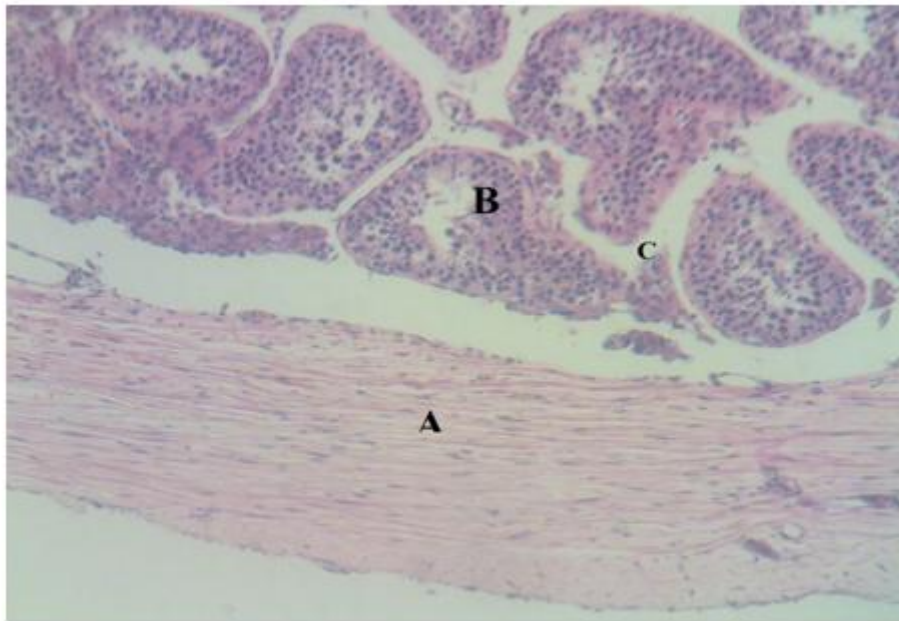


Fig 2: Control group,A-Capsule ,B-Seminiferous tubules, C-leydig cell

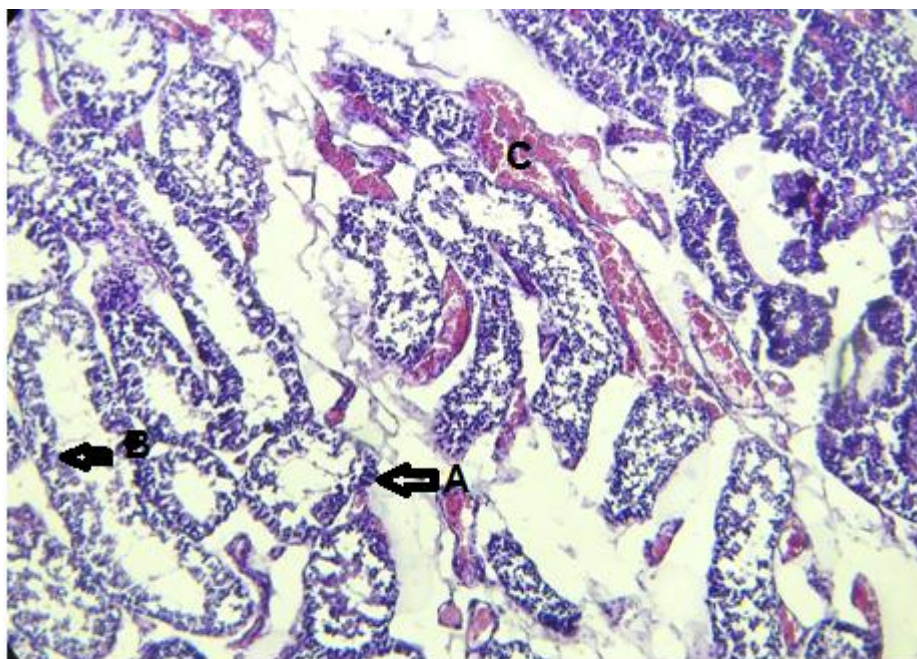


Fig.3: Treated group shown A-seminiferous tubules B-Spermatogenic cells
C-Blood vessels. H&E ,X400

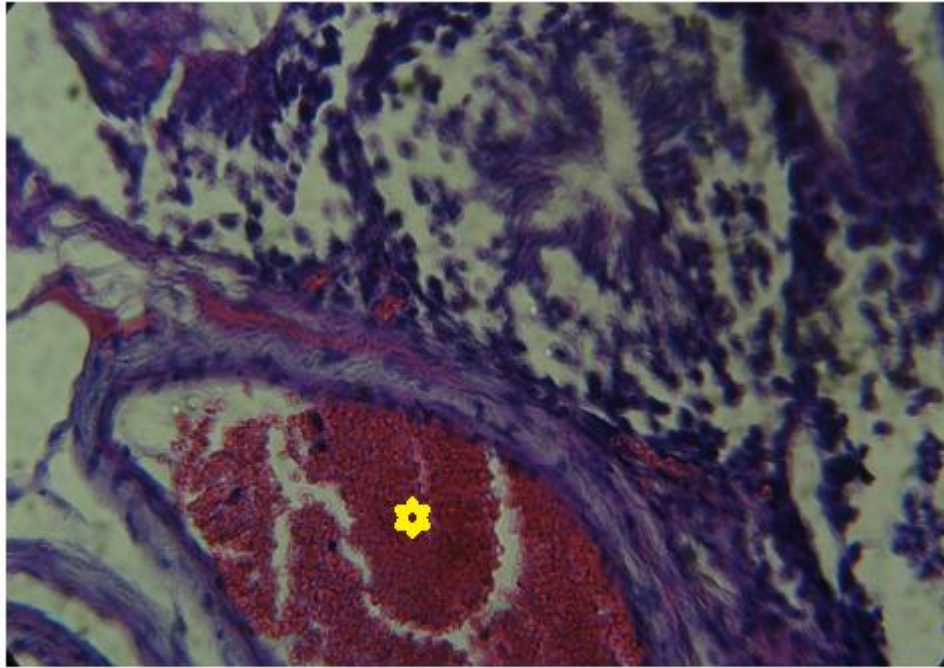


Fig 4: Treated group showing the congested blood vessels · H&E,X 600

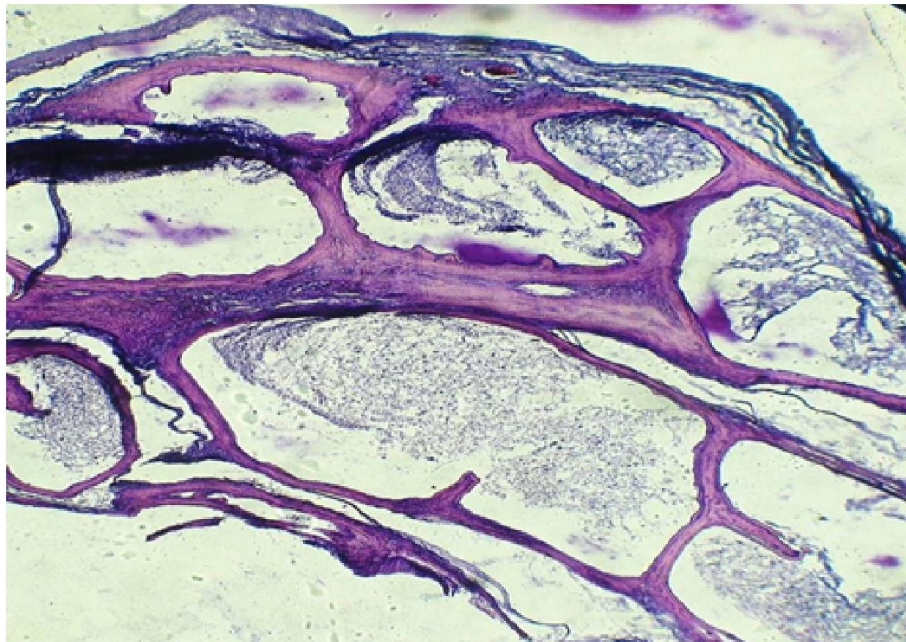


Fig. 5: treated group ,A-Seminiferous tubules, B-Spermatid. H&E ,X600.

DISCUSSION

The histological features in testes illuminated the existence of thin tunica albuginea with different stages of spermatogenic phases in seminiferous tubules that separated with connective tissue, the same effect of propolis investigated by (5).

Our finding agreement with (8) where they investigate that the seminiferous tubules have a small lumen that fills with sperm producing cells than the control group.

The similar results shown by (9) who showed that date palm pollen treatment led to increase in concentration of spermatozoa. And this referred to the increased of LH hormone level which is accountable to promote testosterone secretions from Leydig cell and stimulating the germinal cells to produce spermatozoa (10)

Our result disagreement with (11) who find that the effect of Astragalus Ovinus on sperm parameters leads to significant reductions Sperm count, spermatogonia and Leydig cells, while they increased by using an aqueous suspension of Date palm pollen.

The administration of date palm pollen to the rats suffering from the poison in cadmium alleviated the hypertrophy of the seminiferous tubules and the depletion of spermatids (12)

The bee pollen grains with a great potential for use in herbal medicine. It is suggested that increases the concentration of testosterone,

تأثير المعلق المائي لحبوب لقاح نحل العسل على عملية إنتاج النطف في ذكور الارانب

احسان علي حبيب وعلاء عبد الخالق سواد، زينب بكر

كلية الطب البيطري، جامعة البصرة، البصرة، العراق.

الخلاصة

صممت التجربة للتعرف على التغيرات النسيجية لحبيبات لقاح نحل العسل على الخصية في الارانب، استخدم عشرون من ذكور الارانب المحليه البالغه وقسمت الى مجموعتين، جرعت المجموعه الاولى بالمحلول الملحي الفسلجي الطبيعي فمويا، بينما عوملت المجموعه الثانيه بالمعلق المائي لحبوب اللقاح، اوضحت نتائج الفحص النسيجي زياده في احجام واعداد النبيبات المنويه والتي تحوي على مراحل متعدده من سليفات النطف وفضلا عن غزو للاوعيه الدمويه مقارنة مع مجموعته السيطره.

REFERENCES

- 1-Maria G. R. , Stefan Bogdanov, Ligia B. A.,Teresa S.,Yanina M., Christian F., Francisco F. (2008); Pollen composition and standardization of analytical methods. *Journal of Apicultural Research and Bee World* 47 (2): 156–163.
- 2-Miroslava K., VUKOVIĆ N., Chlebo R., ŠČík P., Katarína R.,J. CUBON J., MaLgorzata D. And Anna P. (2012): The antimicrobial activity of honey, bee pollen loads and beeswax from Slovakia. *Arch. Biol. Sci.*, Belgrade, 64 (3), 927-934.
- 3- Battaa, A. M. El-Neney and El-Kholy K. H. (2014): Effect of natural additive (bee pollen) on immunity and productive and reproductive performances in rabbits. *Egypt. Poult. Sci.* Vol (34) (II): (579-606).
- 4-Mercola, J.(2003). The Use of Bee Pollen as a Superfood, <http://www.shirleys-wellness-cafe.com/bee.htm>.
- 5- Amany A. Abbass, Amel M. El-Asely, Mohamed M.M. Kandiel (2012):
Effects of dietary Propolis and pollen on growth performance, fecundity and some hematological parameters of *Oreochromis niloticus*. *Turkish Journal of Fisheries and Aquatic Sciences* 12: 851-859.
- 6- Alleva ,J.J.;Waleski,M.V.;Alleva,F.R. And Umberger, E.J. (1968): Synchronizing effect Of photoperiodicity on ovulation in hamster. *Endocrinology*.82:123-127.
- 7-Luna, L.G. (1968) Manual of histologic staining methods of the Armed Forces Institute of Pathology. 3rd Edition, McGraw-Hill, New York
- 8- Ihsan R. , Ibrahim A. And Jameel. K. (20120): Effect of *Phoenix dactylifera* pollen grains suspension in fertility of male rats. *Baghdad journal of Science*.9 (4) 575- 583.
- 9- Salman I., Munazza A., Hina M., Tahir S., Yasir A. And Gul-E- Nazish (2014); Evaluation of spermatogenesis in prepubertal albino rats with date palm pollen supplement. *Afr. J. Pharm. Pharmacol*, 8 (2): 59-65.
- 10-El-Mougy, S.A.,Abdel Aziz,S.A. Al-Shanawany M. Omar A. (1991): The Gonadotropic activity of palm in mature male rats. *Alexandria j. Pharmacy Sci*.5; 156-159.
- 11-Mehraban, F., Jafari M., Toori M. ,Sadeghi, H., Joodi B., Mostafazade, M., and Sadeghi H.(2014): Effects of date palm pollen (*Phoenix dactylifera* L.) and *Astragalus ovinus* on sperm parameters and sex hormones in adult male rats. *Iranian Journal of Reproductive Medicine*; 12 (10), 705.

12-Wafaa A. Hassan; Akram M. El-kashlan and Noha A. Ehssan(2012): Egyptian Date Palm Pollen Ameliorates Testicular Dysfunction Induced by Cadmium Chloride in Adult Male Rats. Journal of American Science,,8(4).